



# MRI Knee Mini-Fellowship

## A Guided Online course

*Report with Confidence*

### What's The Mini Fellowship About?

A Guided 30 day course where we cover the Imaging on MRI of intra and extra articular pathologies of the Knee. By the end of the Mini Fellowship you should be much more Confident to Assess and Report MRI of the Knee

### What Do We Cover?

All the relevant Anatomy, Pathology, Clinical and Imaging findings. Where to Look, What to Look For and How to Report them more Confidently.

### How Do You Learn It?

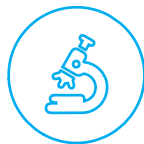Daily posts with a combination of text, images, videos, dicoms, quizzes and the ability to ask questions to Dr Ravi throughout the course to guide you and clear doubts.



Guided Learning



Anatomy



Pathology



Knowledge



Dicoms



Videos



Ask



Quiz



Badges



Certificate CME

### Who's Teaching



Dr Ravi, is the Director of Radiology Education Asia and a Senior Consultant Radiologist from Australia now in Singapore. He has been teaching MSK and Spine MRI for over 10 years and his aim in the courses is not just accumulating facts, but for you to be reporting more confidently at work.

His method of teaching is to simplify, without losing the essential things we need to know. For you to easily recognise the important anatomy, the relevant macroscopic pathology which helps to understand the imaging findings and for you to know where to look and what to look for. All of these help you to report a scan with Confidence and issue reports that you are proud of and will be respected by referrers.

*Report with Confidence*



# REPORT MORE CONFIDENTLY: TOPICS COVERED

## 1. SEQUENCES/ REPORTING STRUCTURE/ APPROACH TO ASSESSING A SCAN

## 2. CARTILAGE

- Normal appearance
- Degeneration: from Fibrillation & Fissuring to delamination and full thickness loss

## 3. MENISCUS

- Normal MRI Anatomy
- Degeneration and differentiation from tears
- Maceration
- Parameniscal Cysts
- Horizontal, Radial, Vertical, Fap tears & Wrisberg rip
- Buckethandle and Root tears

## 4. ACL

- Normal anatomy and MRI Appearance
- Full thickness and Partial tears
- ACL grafts normal appearance and complications

## 5. PCL

- Normal Anatomy and MRI appearance
- Full thickness and Partial tears

## 6. A UNIFIED APPROACH TO MEDIAL KNEE STRUCTURES

- MCL Deep & Superficial
- Posterior oblique ligament
- Menisco capsular separation
- Posteromedial Capsule
- Semimembranosus
- Ramp Lesions
- Normal Anatomy and MRI Appearance
- Strain, Partial and full thickness tears, Ruptures and scarring

## 7. A UNIFIED APPROACH TO LATERAL KNEE STRUCTURES

- Iliotibial Band and Friction
- Segond fractures and the antero lateral ligament
- LCL
- Biceps femoris tendon

- Popliteus Tendon
- Posterolateral Corner
- Normal Anatomy and how to find the structures
- Strain, Partial and full thickness tears and ruptures

## 8. PATELLA TENDON


- Normal
- Tendonosis and Tears
- Fat Pad Impingement

## 9. PATELLA DISLOCATION

- What to look for and how to diagnose it

## 10. PREDISPOSING FACTORS FOR PATELLA DISLOCATION

- Patella alta
- Lateralisation tibial tubercle
- Trochlear Dysplasia



Scan QR Code or Visit  
<http://bit.ly/learnkneemri>  
to register



<https://www.facebook.com/RadEdAsia/>



<https://www.youtube.com/c/radedasia>



<https://www.linkedin.com/in/radedasia/>



<https://radedasia.com/>



<https://www.instagram.com/radedasia>



<https://wa.me/6594882623>



<https://twitter.com/RadEdAsia>



<https://t.me/radiologyedasia>

## CPD FOR THE COURSE

30 CPD Hours for web-based learning by the Royal Australian and New Zealand College of Radiologists (RANZCR). RANZCR CPD/CME are recognised by most international licensing agencies. Please check with your licensing agency.

