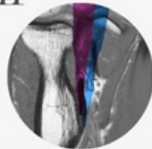
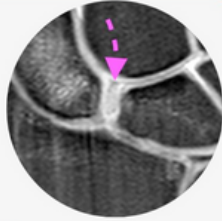



GUIDED ONSITE WRIST, HAND & ELBOW MRI MINI-FELLOWSHIP



Report with Confidence

WWW.RADEDASIA.COM

WHY DO THE MINI FELLOWSHIP?

- With our **Guided Onsite MRI WRIST, HAND & ELBOW** Mini Fellowship, learn to become **More Confident to Assess, Accurately Diagnose** and issue **Reports that are Respected**.
- Structured, guided, hands on learning on workstations where you can ask questions and clear doubts for you to become more **Confident** in reporting. Focusing on what you need to do at work **Where to Look, What to Look for and How to Best Report it**.

CPD/CME POINTS

- CPD Points by the Royal Australian and New Zealand College of Radiologists (RANZCR) recognized by most licensing agencies & CPD from the Malaysian Medical Association. Number of points will be confirmed shortly.

SEE HOW & WHAT YOU WILL LEARN

[Click Image below](#)



WHAT YOUR COLLEAGUES SAY

“Teaching of the detailed anatomy was brilliant. Brilliant exemplary images as well. Big thank you to everyone in the team and especially Dr Ravi.”

DR THOMAS
UNITED KINGDOM

“Excellent course. It's almost perfect, Advanced version fellowship with more extensive teaching. You have created a great learning platform.”

DR JACHIMOWIZ
NORWAY

“Boosted my confidence in reporting Elbow MRI imaging. Very detailed guided instructions on anatomy & pathology. Simple explanations but explaining complex topics.”

DR PHINDILE
SOUTH AFRICA

“Brilliant course once gain. The best there is. Impressive presentation, Dr Ravi's explanations and the beautiful images. A very well laid out and practical course.”

DR THANH
AUSTRALIA

WHO'S TEACHING

Dr Ravi Padmanabhan is the Director of Radiology Education Asia. Originally from Australia and now based in Singapore, he works in MSK and Spine MRI, CT and Ultrasound Imaging and Intervention. He teaches by simplifying complex topics into what's essential, with the focus on what matters... **Making daily reporting Easier, Accurate and More Confident.**

WHO'S TEACHING

Dr Colin Chong is a MSK and Interventional Radiologist in Brisbane Australia. He provides specialist MSK imaging for elite athletes and professional sporting teams & is actively involved in teaching, publications and research. He has presented at multiple conferences.

WHAT YOU WILL LEARN TO MAKE YOUR DAILY REPORTING EASIER, MORE ACCURATE AND CONFIDENT

In all topics we cover the normal appearance, anatomy, relevant macroscopic pathology and learn **Where to look, What to look for and How to report** it with the aim of **Making daily reporting Easier, Accurate and More Confident.**

WRIST & HAND

1. SEQUENCES/ HOW TO ASSESS/ REPORTS

- The best sequences to use
- A pattern to assess the scan and
- A structure for reporting so that nothing is missed

2. TENOSYNOVITIS

- Learn the recurring MRI patterns of tenosynovitis that you can apply to most tendons.

3. DE QUERVAIN'S TENOSYNOVITIS

- Imaging Appearance & How to Report De Quervain's Tenosynovitis

4. INTERSECTION SYNDROME

- Imaging Appearance & How to Report Intersection Syndrome.

5. DRUJ

- Learn the Imaging anatomy of the DRUJ and the common abnormalities seen.

6. TFCC

- Complex structure but learn how to confidently identify, assess and report the various components of the TFCC and its common abnormalities.

7. SCAPHOID FRACTURES, SCAPHO-LUNATE LIGAMENT & INSTABILITY

- Identify and report Fractures, Ligamentous tears, Osteonecrosis and Scapho-Lunate Instability.

8. EXTRINSIC WRIST LIGAMENTS

- Learn the various components of the extrinsic ligaments. How to identify the ligaments and Diagnose & Report Strains and Tears.

9. MCPJ AND FINGER LIGAMENTS AND TEARS

- Learn to Identify the imaging anatomy of the Ligaments and Volar Plate and then learn how to assess and report Strains, Tears and Avulsions.

10. THUMB MCPJ LIGAMENTS AND STENNER LESIONS

- Learn to identify the imaging anatomy of the Thumb ligaments and learn how to assess and report Strains, Tears, Avulsions and Stenner Lesions.

11. STT & 1st CMC JOINT DEGENERATION

- Assessing degeneration of the 1st Carpo Metacarpal and STT joint

12. MEDIAN NERVE ASSESSMENT

- Identifying the median nerve at the wrist and assessing for compression.

ELBOW

1. ELBOW SEQUENCES/ REPORTING STRUCTURE/ HOW TO ASSESS

- The best sequences to use
- A pattern to assess the scan and
- A structure for reporting so that nothing is missed

2. NORMAL VARIANTS

- Learn to recognize & how to report the various normal variants that mimic Pathology

3. BICEPS/TRICEPS/BRACHIALIS TENDONS

- Imaging Anatomy, Pathology & MRI appearance of Tendinosis, Tears, Avulsions, & Bony changes and How to Report.

4. BURSAE

- The various elbow bursae and their complications.

5. LATERAL EPICONDYLITIS & COMMON EXTENSOR ORIGIN

- Imaging Anatomy, pathology & MRI appearance and how to report Lateral Epicondylitis & Tears and their relationship to the Lateral Collateral Ligament.

6. LATERAL COLLATERAL LIGAMENT (LCL)

- The various components of the LCL & their relationship to the Common Extensor Origin. Recognise & Assess Strains, Tears and Common extensor Tear extensions

7. POSTERO LATERAL ROTATORY INSTABILITY (PLRI)

- What is it and why does it matter? Anatomy, pathology and the Imaging appearance of PLRI.

8. MEDIAL EPICONDYLITIS & COMMON FLEXOR ORIGIN

- Learn the Anatomy, pathology and the Imaging appearance
- How to recognise & assess Medial Epicondylitis and Tears.

9. ULNAR COLLATERAL LIGAMENT (UCL)

- The various components of the UCL. Recognize, Assess and Report Strains, Tears and Avulsions.

10. ULNAR NERVE NEURITIS (CUBITAL TUNNEL)

- Imaging anatomy and how to assess the cubital tunnel and the features of ulnar neuritis.

11. POSTERIOR INTEROSSEOUS NERVE (PIN)

- Learn the Anatomy, pathology and the Imaging appearance of PIN Entrapment.

REGISTER: [CLICK HERE](#)