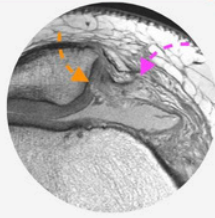




# GUIDED ONLINE KNEE MRI MINI-FELLOWSHIP



For CTMRISP Fellows and  
Fellows in Training

*Report with Confidence*

30 CPD Hours for Web Based Learning by the Royal Australian and New Zealand College of Radiologists (RANZCR)

## WHY DO THE COURSE?

- With our Guided Online MRI KNEE Mini Fellowship learn to become **More Confident in Assessing Knee MRIs**, Making an **Accurate Diagnosis** and issuing reports **Respected by Clinicians**.
- Structured, guided learning for you to become more confident in assessing and reporting Knee MRI by focusing on how you would assess scans at work by learning **Where to Look, What to Look for and How to Best Report it**.

- Importantly, the course is **Guided** and you are not left on your own. Ask questions, clear doubts like an actual fellowship. (Click on image below to see more on how and what you will learn.)
- Through this Knee MRI Mini Fellowship we aim to make you **More Confident to Assess, Make a Diagnosis** and issue **Reports Respected** by Clinicians.

## SEE HOW & WHAT YOU WILL LEARN:

Click Image below



## WHO'S TEACHING

Dr Ravi Padmanabhan is the Director of Radiology Education Asia. Originally from Australia and now based in Singapore, he works in MSK and Spine MRI, CT and Ultrasound Imaging and Intervention. He teaches by simplifying complex topics into what's essential, with the focus on what matters... **Making daily reporting Easier, Accurate and Confident.**

## WHAT YOUR COLLEAGUES SAY

“ I appreciate the efforts of Dr. Ravi, who is behind the best radiology course I have taken so far, which has taken me considerably further than any book in a relatively short time. ”

**Dr LIGART**  
GERMANY

“ The Dicoms/Video-explanation is excellent. Q&A explanations is beyond great. I usually found it very illuminating as it brings a different view or another angle on the concepts & problems. ”

**Dr EDUARDO**  
PANAMA

“ Guided approach, innovative teaching method. It builds you up from the basic like anatomy and takes u to the post op graft level. Wonderful online course experience! ”

**Dr GAGELA**  
SOUTH AFRICA

“ The simplicity of the explanations and the opportunity to look at a case and then get an answer on the case. Great learning experience. ”

**Dr CORNELIA**  
NEW ZEALAND

## CPD/CME

30 CPD Hours for web-based learning by the Royal Australian and New Zealand College of Radiologists (RANZCR). RANZCR CPD/CME is recognised by most international licensing agencies.

# WHAT YOU WILL LEARN TO ASSESS AND REPORT MORE CONFIDENTLY IN 30 DAYS

In all topics we cover the normal appearance, anatomy, relevant macroscopic pathology and learn **Where to look, What to look for and How to report it** with the aim of **Making daily reporting Easier, Accurate and More Confident.**

## 1. SEQUENCES/ REPORTING STRUCTURE/ HOW TO ASSESS

- The best sequences to use, a pattern to assess the scan and a structure for reporting so that nothing is missed.

## 2. CARTILAGE: WHAT TO LOOK FOR AND REPORT

- Start by knowing the Normal appearance
- The various forms of Cartilage Degeneration
  - Fibrillation & Fissuring
  - Delamination
  - Full thickness loss
- The underlying Bone Changes that can occur

## 4. MENISCUS

- Begin by knowing the Normal MRI Anatomy and appearance
- Learn the various types of Degeneration and how to differentiate from tears
- Maceration: What is it and How to diagnose & Report
- The different types of Parameniscal Cysts
- All the tears
  - Horizontal, Radial, Vertical and Complex
  - Flap and displaced tears
  - Wrisberg rip
  - Bucket handle
  - Root tears
- Discoid Meniscus

## 5. ACL

- Normal anatomy and MRI Appearance
- Diagnose and How to Report Full thickness & Partial tears
- The secondary signs of ACL tears
- ACL grafts normal appearance and complications
- Mucoïd Degeneration

## 6. PCL

- Normal anatomy and MRI Appearance
- Diagnose and How to Report Full thickness & Partial tears
- Mucoïd Degeneration

## 7. A UNIFIED APPROACH TO MEDIAL KNEE STRUCTURES

These structures are interconnected and can be complex. You learn a method to find and assess them more easily and report them in a structured way

- MCL Deep & Superficial
- Posterior oblique ligament
- Menisco capsular separation
- Posteromedial Capsule
- Semimembranosus
- Ramp Lesions
- Pes Anserine Bursa
- Deep MCL Bursa
- Learn the Normal anatomy and MRI Appearance and then learn to assess and report their pathology.
- Strain, Partial and Full thickness tears, Ruptures and Scarring of ligaments and tendons and bursal inflammation.

## 8. A UNIFIED APPROACH TO LATERAL KNEE STRUCTURES

These structures are interconnected and can be complex. You learn a method to find and assess them more easily and report them in a structured way

- Iliotibial Band and Friction
- Segond fractures and the antero lateral ligament
- LCL
- Biceps femoris tendon
- Popliteus Tendon
- Posterolateral Corner Structures
- Popliteo Meniscal Fascicles

- Learn their Normal Anatomy and MRI Appearance and then learn to assess and report their pathology.
- Strain, Partial and Full thickness tears, Ruptures and Scarring.

## 9. PATELLA TENDON & BURSA

- Begin with the Normal anatomy and MRI appearance
- Then learn to recognise, assess and report
  - Tendinosis
  - Tears
  - Fat Pad Impingement
  - Patella Bursa

## 10. PATELLA DISLOCATION

Learn a structure to diagnosing, assessing for predisposing factors and reporting Patella Dislocation

- The findings to look for to confirm Patella Dislocation
- The Ligament and Cartilage injuries you need to look for
- A simple method to find the MPFL an important ligament to assess for the surgeon.

## 11. PREDISPOSING FACTORS FOR PATELLA DISLOCATION

- Just diagnosing Patella Dislocation isn't enough. You also need to assess and report on predisposing factors
- Learn to assess for
  - Patella Alta
  - Lateralisation of the tibial tubercle
  - Trochlear Dysplasia

## 12. EFFUSIONS AND SYNOVITIS

- Learn the different appearances of Synovitis
- Learn to recognise and differentiate simple and complex effusions and
- Lipohaemarthrosis