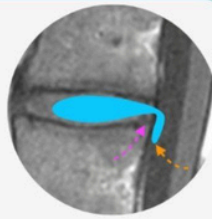




# GUIDED ONLINE SPINE & SIJ DEGENERATIVE DISEASE MRI MINI-FELLOWSHIP



*Report with Confidence*

## WHY DO THE COURSE?

- With our Guided Online MRI DEGENERATIVE SPINE & SIJ Mini Fellowship become **More Confident** assessing Spine MRIs, Making an **Accurate Diagnosis** and issuing reports **Respected** by Clinicians.
- Structured, guided learning for you to become more confident in assessing and reporting Spine MRI focusing on how you would assess scans at work...  
[Where to Look, What to Look for and How to Best Report it.](#)

- Importantly, the course is **Guided** and you are not left on your own. Ask questions and clear doubts like an actual fellowship.
- Through this Spine and SIJ Degeneration MRI Mini Fellowship we aim to make you **More Confident with your Diagnosis** and issue **Reports Respected** by Clinicians.

## SEE HOW & WHAT YOU WILL LEARN:

[Click Image below](#)



## WHO'S TEACHING

Dr Ravi Padmanabhan is the Director of Radiology Education Asia. Originally from Australia and now based in Singapore, he works in MSK and Spine MRI, CT and Ultrasound Imaging and Intervention. He teaches by simplifying complex topics into what's essential, with the focus on what matters... **Making daily reporting Easier, Accurate and Confident.**

## WHAT YOUR COLLEAGUES SAY

“ Practical & useful knowledge. Excellent format, it definitely beats hands down the usual methods of conferences, presentations & journals. Feel lucky to have taken it.

 **Dr ADAM**  
NORWAY

“ Gratitude for a great course. Teaching of Concepts was good and cleared a lot of doubts which I had during my routine practice. Learn at your own pace and time.

 **Dr MATAS**  
LITHUANIA

“ I have gained the most from this mini-fellowship. Great learning the whys of protocols and pathologies and modifying my practice for the best outcomes.

 **Dr ABUSAYO**  
NIGERIA

“ The structure of the fellowship is very organized & comprehensible. Learning platform is very easy to use. The way Dr Ravi teaches is reflected in how this online fellowship was structured. Excellent!

 **Dr JOANNE**  
PHILIPPINES

## CPD/CME

30 CPD Hours for web-based learning by the Royal Australian and New Zealand College of Radiologists (RANZCR). RANZCR CPD/CME are recognised by most international licensing agencies.

## WHAT YOU WILL LEARN TO ASSESS AND REPORT MORE CONFIDENTLY IN 30 DAYS

In all topics we cover the normal appearance, anatomy, relevant macroscopic pathology and learn **Where to look, What to look for and How to report** with the aim of **Making your daily reporting Easier, Accurate and More Confident.**

### 01. MRI SEQUENCES & SCAN PLANES

- The essential sequences & planes and when to use them.
- Which sequence is best to find each pathology.
- When to give contrast.

### 02. LEARN A PATTERN TO ASSESS EACH REGION

- Cervical Spine.
- Thoracic Spine.
- Lumbar Spine.
- SIJ.

### 03. VARIANTS YOU NEED TO KNOW

- Conjoint Nerve Roots.
- Low Conus.
- Transitional Lumbosacral Anatomy: How to Identify, How to Number & How to Report.

### 04. DISC DEGENERATION: ALL YOU NEED TO KNOW

- Imaging appearance, progression and variations.
- Modic Changes recognize the different types.

### 05. NERVE ROOTS

- What's the normal distribution at different levels.
- Identifying traversing & exiting roots.
- Conjoint Nerve Roots: How to identify & determine the nerve compressed.

### 06. DISC HERNIATIONS

- How to find & differentiate the different types, the specific locations to check and the best planes to visualize them.
- Learn how to assess and report their effect on the cord, canal, recess, foramen & nerve roots.

### 07. STENOSIS: LEARN TO ASSESS THE EFFECT ON NERVE ROOTS BY

- Canal Stenosis.
- Subarticular/Lateral Recess Stenosis.
- Foraminal Stenosis.

### 08. FACET DISEASE: LEARN TO RECOGNIZE

- Normal Facets and Facet Arthritis.
- Effect of facet hypertrophy on the canal, foramen & nerve roots.
- Facet cysts and their effect on the canal, foramen & nerve roots.

### 09. SPONDYLOLISTHESIS/LYSIS

- Where and How to look for it.
- Traumatic: How to find the earliest signs (where treatment is possible) to established lysis.
- The specific sequences you need to use to find early traumatic Spondylolysis.
- How to differentiate Traumatic vs Degenerative spondylolisthesis.
- The effect on the canal, foramen, facets and nerve roots.

### 10. BAASTRUP'S

- Where to look, What to look for & How to report it.
- Recognise the signs of active inflammation.

### 11. BERTOLOTTI SYNDROME

- Where to look, What to look for & How to Report it.
- Recognise the signs of active inflammation.

### 12. ARACHNOIDITIS

- Learn how the normal nerve root distribution changes.
- The various patterns of arachnoiditis to look for.
- The CSF complications of arachnoiditis.

### 13. POST OPERATIVE CHANGES

- Normal Post Op appearance.
- Post Op Seromas and Pseudomeningocles.
- Post op Arachnoiditis.
- Epidural Scarring/Fibrosis where & what to look for.
- How to differentiate scarring from recurrent disc.
- Adjacent Segment Disease (ASD): What to look for.

### 14. TARLOV CYSTS

- Learn to find and differentiate Perineural & Paraneural Tarlov cysts and determine their effect on nerve roots.

### 15. SIJ: HOW TO IDENTIFY

- The Fibrous & Cartilaginous components.

### 16. SIJ: DEGENERATION & TRAUMA

- Learn to recognize Degenerative Changes.
- How to find Fractures & differentiation from Bone Bruising.

### 17. SIJ: OSTEITIS CONDENSANS ILII

- Learn how to diagnose it and,
- How to differentiate from Sacroiliitis.