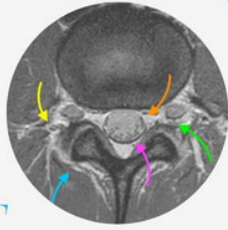




SPINE & SIJ IMAGING FOR PAIN MANAGEMENT



A GUIDED ONLINE
MINI-FELLOWSHIP

Assess with **Confidence**

WHY DO THE COURSE?

"I wouldn't plan or do any Spine Intervention without being able to assess the scan myself and definitely wouldn't rely just on a report. It's essential to be able to assess your patients' scans for yourself when treatment and intervention is being planned.

This Mini Fellowship aims to reduce your struggle with interpreting your patients' Spine & SIJ imaging when planning treatment and doing intervention. "

SEE HOW & WHAT YOU WILL LEARN:

[Click Image below](#)



WHO'S TEACHING

Dr Ravi Padmanabhan is the Director of Radiology Education Asia. Originally from Australia and now based in Singapore, he works in MSK and Spine MRI, CT and Ultrasound Imaging and Intervention. He has been teaching MSK and Spine MRI and CT for over 15 years and working in it for much longer.

This course has been developed in conjunction with input from colleagues in Pain Medicine, Sports Medicine, Orthopaedics and Neurosurgery for what you need to learn to quickly assess your patients' Spine & SIJ MRIs & CTs yourself prior to you doing any intervention.

WHAT YOUR COLLEAGUES SAY

“ A very good course. Highly recommended for clinicians other than radiologists who deal with xrays, CT and MRI scans in their daily practice and have to rely on radiologist reports most of the time. ”

Dr NASSER
Ireland

“ Thank you, Dr Ravi ! Sustained learning. Manageable volume of information each day Great course! Helped to improve my confidence. Will sign up for more. ”

Dr WILSON
USA

“ Well-structured and excellent explanations. Each day's teaching was the right amount of study - enough to learn but not to overwhelm you. Excellent course ! ”

Dr MOSTOFA
EGYPT

“ Thank you for the amazing course, impressive and unique teaching experience. Really Learned a lot from the course. It's very useful for daily work. Thanks a lot! ”

Dr HUI
SINGAPORE

CME/ CPD

30 CPD hours for web based learning by the Royal Australian and New Zealand College of Radiologists (RANZCR). These points are recognized by most international licensing agencies.

WHAT YOU WILL LEARN TO ASSESS AND REPORT MORE CONFIDENTLY IN 30 DAYS

In all topics we cover the normal appearance, anatomy, relevant macroscopic pathology and learn **Where to look, What to look for and How to report** with the aim of **Making your daily reporting Easier, Accurate and More Confident.**

01. MRI SEQUENCES & CT

- The essentials you need to know without the physics.
- Easily differentiate MRI sequences.
- Which sequences you must request.
- Which sequence is best to find each pathology.
- When to request contrast.
- CT: Angled reformats, Bone vs soft tissue, When to give contrast.

02. LEARN A PATTERN TO QUICKLY ASSESS EACH REGION OF YOUR PATIENT'S CT/MRI

- Cervical Spine.
- Thoracic Spine.
- Lumbar Spine.
- SIJ.

03. VARIANTS YOU NEED TO RECOGNIZE

- Conjoint Nerve Roots.
- Low Conus.
- Transitional Lumbosacral Anatomy: How to Identify & How to Number.

04. DISC DEGENERATION: ALL YOU NEED TO KNOW

- Imaging appearance, progression & variations.
- Modic Changes recognize the different types.

05. NERVE ROOTS

- What's the normal distribution at different levels.
- Identifying traversing and exiting roots.
- Learn to recognize Arachnoiditis.
- Conjoint Nerve Roots: How to identify, determine the nerve compressed and its relevance to the level for intervention.

06. DISC HERNIATION

- Learn to find the types & the specific locations to check.
- Learn how to assess their effect on the cord, canal, recess, foramen and nerve roots.

07. STENOSIS: LEARN TO RECOGNIZE & THEN ASSESS THE EFFECT ON NERVE ROOTS

- Canal Stenosis.
- Subarticular/Lateral Recess Stenosis.
- Foraminal Stenosis.

08. FACET DISEASE: LEARN TO RECOGNIZE

- Normal Facets & Facet Arthritis.
- Effect of facet hypertrophy on the canal, foramen and nerve roots.
- Facet cysts & their effect on the canal, foramen & nerve roots.

09. SPONDYLOLISTHESIS/LYSIS

- Where and How to look for it.
- Traumatic: How to find the earliest signs (where treatment is possible) to established lysis.
- The specific sequences you need to request to find early traumatic Spondylolysis.
- How to differentiate Traumatic vs Degenerative spondylolisthesis.
- The effect on the canal, foramen, facets & nerve roots.

10. BAASTRUP'S

- Where to look, What to look for & How to find it.
- Recognize the signs of active inflammation that may benefit from intervention.

11. BERTOLOTTI SYNDROME

- Where to look, What to look for & How to find it.
- Recognize the signs of active inflammation that may benefit from intervention.

12. POST OPERATIVE CHANGES

- Normal Post Op appearance.
- Post Op Seromas and Pseudomeningocles.
- Post op Arachnoiditis.
- Epidural Scarring/Fibrosis where and what to look for.
- How to differentiate scarring from recurrent disc.
- Adjacent Segment Disease (ASD): What to look for.

13. TARLOV CYSTS

- Learn to find and differentiate Perineural and Paraneural Tarlov cysts and determine their effect on nerve roots & your planning for spinal injections.

14. SIJ: HOW TO IDENTIFY

- The Fibrous & Cartilaginous components.

15. SIJ: DEGENERATION vs SPONDYLOARTHRITIS

- Learn to recognize Degenerative Changes.
- Learn to recognize Spondyloarthritis.
- How to differentiate the two.

16. SIJ: OSTEITIS CONDENSANS ILII

- Learn how to diagnose it and,
- How to differentiate from Sacroiliitis.

17. SIJ: TRAUMA

- How to find Fractures & differentiation from Bone bruising.